

IMAGING PERFORMED BY

IntraPet.com



Clinical Sonography & Telecytology

EDUCATIONAL TELECONSULTATION SERVICES™

1-800-838-4268 info@sonopath.com SonoPath.com

PATIENT

Gracie Ley

SPECIES

Feline

BREED

DSH

SEX

Female Spayed

AGE

1.30.11

WEIGHT

6.8lbs

INTERPRETED BY

Maggie Machen Lamy,
DVM, DACVIM
(Cardiology)

HOSPITAL NAME

Banfield Columbia

REFERRING VET

Dr. Hirsch

INVOICE

24868

DATE

6.9.22

PRESENTING CLINICAL SIGNS

History: Losing weight. Grade 2-4/6 heart murmur.

-Abnormal lab results: Cbc/chem/T4 performed 3/2/2022 had a WBC of 28,000 with neutrophilia but otherwise unremarkable. repeat bloodwork 6/3/2022 wnl. UA USG 1.050

-Sedation used: Sedated with Alfaxone.

-STAT: Not requested

-Imaging performed by: Andi Parkinson, BS, RDMS.

*Sedated with alfaxalone

ECHOCARDIOGRAM FINDINGS

2D, m-mode, color flow and doppler imaging is available. The left ventricular wall is normal in dimension. There is a diffusely hyperechoic endocardium consistent with fibrosis. The papillary muscles are mildly remodeled, hypertrophied and hyperechoic. The left atrium is normal in size. The right atrium is normal in size. Mild to moderate TR; normal velocity. The right ventricle appears normal. The mitral valve is normal in structure and mobility. Blood flow through both the LVOT and RVOT are decreased in velocity (due to sedation). No pleural or pericardial effusion seen. No obvious cardiac tumors.

CARDIAC CHART

FELINE CARDIAC PARAMETERS	BODY WEIGHT (kg)	HR (BPM)	IVSd (cm) <small>(Moise, Pipers)</small>	LVIDd (cm) <small>(Moise, Pipers)</small>	LWVd (cm) <small>(Moise, Pipers)</small>	FS (%)	EF (%)
NORMAL PARAMETER	-----	150-240	3.5-0.55	<2 (mean 1.5)	3.5-0.55	35-67	80-100
PATIENT	3.1	122	0.53	1.2	0.40	38	73
FELINE CARDIAC PARAMETERS	LA/AO <small>(Boon)</small>	LA/AO HEART BASE (Swe) <small>(Abbott)</small>	LA 2D short axis Base view (cm) <small>(Abbott)</small>		LVOT VEL (m/s)	RVOT VEL (m/s)	E max (m/s)
NORMAL	<1.5	<1.3	<1.2		<1.6	<1.3	<0.9
PATIENT	NM	1.0	1.0		0.55	0.5	NM

Adapted from June Boon, Veterinary Echocardiography, 1998
Abbott J & MacLean H JVIM 2006;20: 111-119, Moise et al. Am J Vet Res 47:1476, 1986. Pipers et al. Am J Vet Res 40:882, 1979.

INTERPRETATION OF THE FINDINGS & FURTHER RECOMMENDATIONS

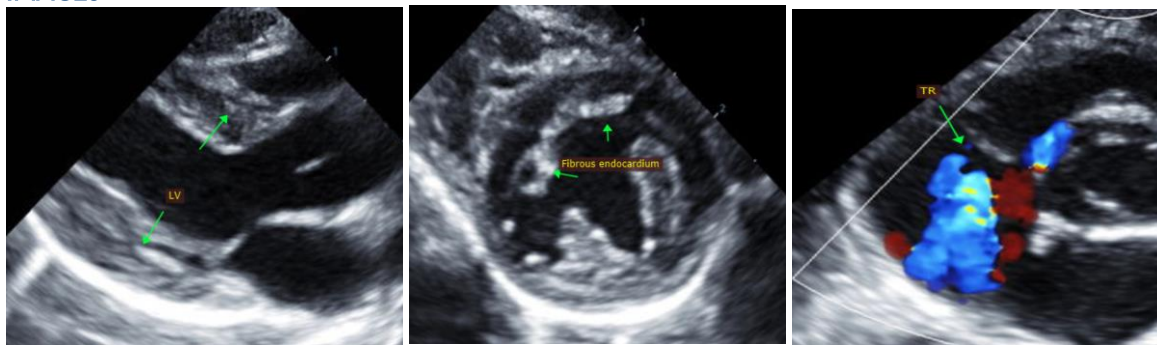
Essentially normal cardiac structure and function. The LV wall thickness is normal and there is no evidence of elevated left atrial pressure. The endocardium is quite remodeled with fibrosis which may be a normal variant or represent early restrictive disease. Mild/moderate TR is also noted, which is of unknown clinical significance. This may represent early degeneration of the valve or may simply be a physiologic/chronic finding not previously appreciated. Monitoring is advised. The RA does not appear dilated at this time however, indicating clinical stability. Serial echocardiography will be necessary to determine progression. No additional issues are identified.

Given these findings, no medications are indicated.

Anesthetic risk is considered mild. With this degree of remodeling and diastolic stiffening, there is an elevated risk for fluid overload in this patient and judicious IV fluid use is recommended. Heart rate stimulating drugs such as atropine, glycopyrrolate or ketamine should be avoided unless medically necessary. A reasonable protocol includes opioid/benzodiazepine premedication, propofol induction, isoflurane maintenance.

Recommend recheck echocardiogram in 1 year to assess for progression.

IMAGES



The information and recommendations provided are based on the images presented by the referring veterinarian. No evaluation can be communicated regarding pathology that was not visible in the image/video clips provided.

Thank you for this referral. This report was generated using transcription software, and minor dictation errors may be present. If the clinical or image interpretation does not parallel your findings or if I can be of any further assistance, please contact me.

Maggie Machen Lamy, DVM
Diplomate of the American College of Veterinary Internal Medicine (Cardiology)
info@sonopath.com